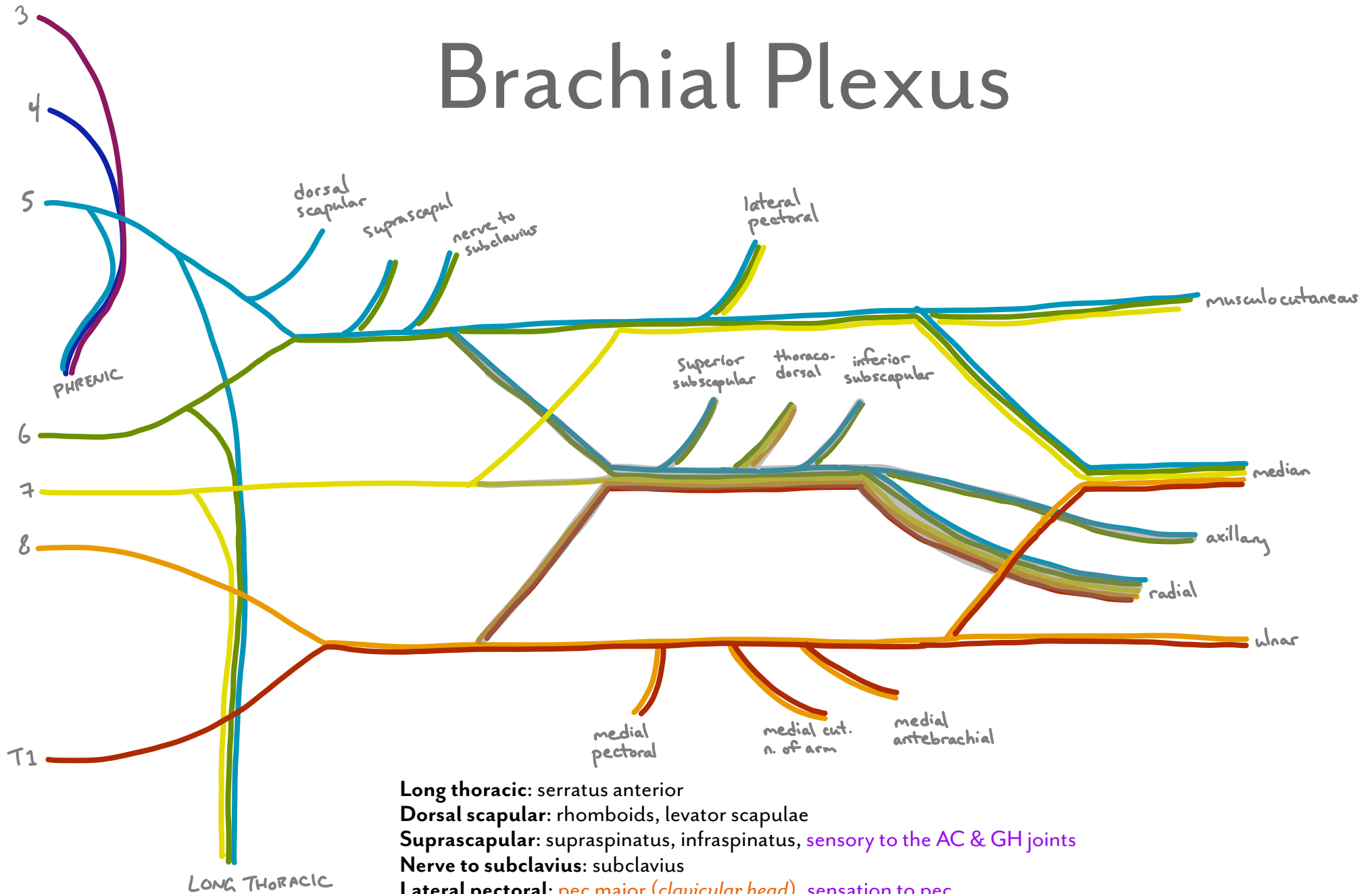


# Brachial Plexus



- Long thoracic:** serratus anterior
- Dorsal scapular:** rhomboids, levator scapulae
- Suprascapular:** supraspinatus, infraspinatus, *sensory to the AC & GH joints*
- Nerve to subclavius:** subclavius
- Lateral pectoral:** pec major (clavicular head), *sensation to pec*
- Superior subscapular:** subscapularis (upper part)
- Thoracodorsal (aka middle subscapular):** lat dorsi
- Inferior subscapular:** subscapularis (lower part), teres major
- Medial pectoral:** pec minor, pec major (sternocostal head)
- Medial cutaneous n. of arm:** *sensory to medial surface of arm (tiny area)*
- Medial cutaneous n. of forearm (antebrachial cutaneous):** *sensory to skin over biceps and medial forearm*